# Case Reports: Treatment of Oral Soft Tissue Lesions and Wounds with High Functional Tooth Paste made from Nanoemulsion Gel

Chang-Hoon Chae, Dong-Ju Choi*, Hae-Young Shim**, Eun-Sun Byun***, Soon-Min Hong****, Yang-Ho Park****, Jun-Woo Park****

*Institute of Nano-Bio Fusion Technology, NanoCureTech Inc, *Life Dental Hospital, Seoul,*
***Dept. of Dentistry, Boramae Hospital, ***Dept. of Orthodontics, College of Dentistry, Seoul National University,*
*****Dept. of Dentistry, College of Medicine, Hallym University*

It is a gel type high functional toothpaste containing vitamin C, E, propolis extract and the rest of herb with a nanoemulsion state. Vitamin C, E is known as the material with an eminent anti-oxidation effect. Propolis is known as the material with an antimicrobial and anti-inflammatory effect. We have been succeeding in making nanoemulsion of vitamin C, E and propolis through the high pressure homogenizer using stable oil and lecithin and the gel type high functional tooth paste were made from nanoemulsion of vitamin C, E and propolis.

We observed the process of wound protecting effect and cure effect for a wound of soft tissue, gingival tissue and mucous membrane showing ulcer and inflammation in oral cavity after applying a gel type high functional toothpaste to patient. As a result, the wound were healed very fast and any side effects were not shown.

We confirmed that a gel type high functional toothpaste with nanoemulsion of vitamin C, E and propolis extract has good effect not only for wound healing but also for treatment of ulcer-like lesion in oral cavity. So we report our cases with review of literatures.

**Key words**
Nanoemulsion, Gingival, Mucosa, High Functional Tooth paste

## INTRODUCTION

Drug Delivery System is a system in which an adminis- tered drug reaches the target effectively. In order to use DDS, high-level techniques to determine the size of the drug, means of transmission, actual target site are required. And so nanotechnology has been the issue these days. Traditional nanotechnology was confined to electronics. However, recently nanotechnology has been applied to variosu fields including pharmacy, medicine, militaries, energy, and environment. Many countries including the United States have a good viewpoint on the development of nanotechnology and the American government has estimated a budget of 1 billion dollars which is one fourth of the world wide budget for nanotechnology. Research on Nanotechnology of the DDS has been active in chemotherapy and dermatology, and in the field of dentistry, Sangi corporation of Japan has invented dental filling material(medical hydroxyapatite) that could be calibrated to the nanometers. In Korea, no research of nano DDS has been reported in the field of dentistry. Oral mucosa and periodontal tissues could be visibly observed to find out the state of the lesion and therefore they are good for inventing a new drug.

The main function of the periodontal tissue is prevent- ing invasion of microorganisms. Therefore breakdown of

* Corresponding author
Jun-Woo Park
Dept. of OMFS, Kang Dong Sacred Heart Hospital, Hallym Univ.
445 Gil-dong, Gangdong-gu, Seoul, 134-010, Korea

the periodontal tissues either from infection, trauma, or inflammation could result in the loss of the teeth, and it is important to maintain periodontal health in order to prevent the loss of teeth. In regards to the importance of the periodontal tissues and the new nano technology in DDS, a high-functional gel has been inveted in Korea. This gel contains nano-sized elements that could be also used as a toothpaste which is called NBF gingival gel(Nano Curetech, Seoul, Korea). Indications are as follows; peridontal and gingival diseases, removal of plague and treatment of halitosis. This study focuses on the healing effect of NBF gingival gel by introducing cases in which healing was augmented by using the gel.

## CASE REPORT

Case 1: A Flapless implant was placed on the right mandibular molar area. The patient showed gingival bleeding and redness which indicated actue inflammation. Under local anesthesia, curettage was done and NBF gingival gel was applied. After 24 hours, inflamma- tory signs including bleeding and redness were within normal range, and healing was accelerated. (Fig 1.)

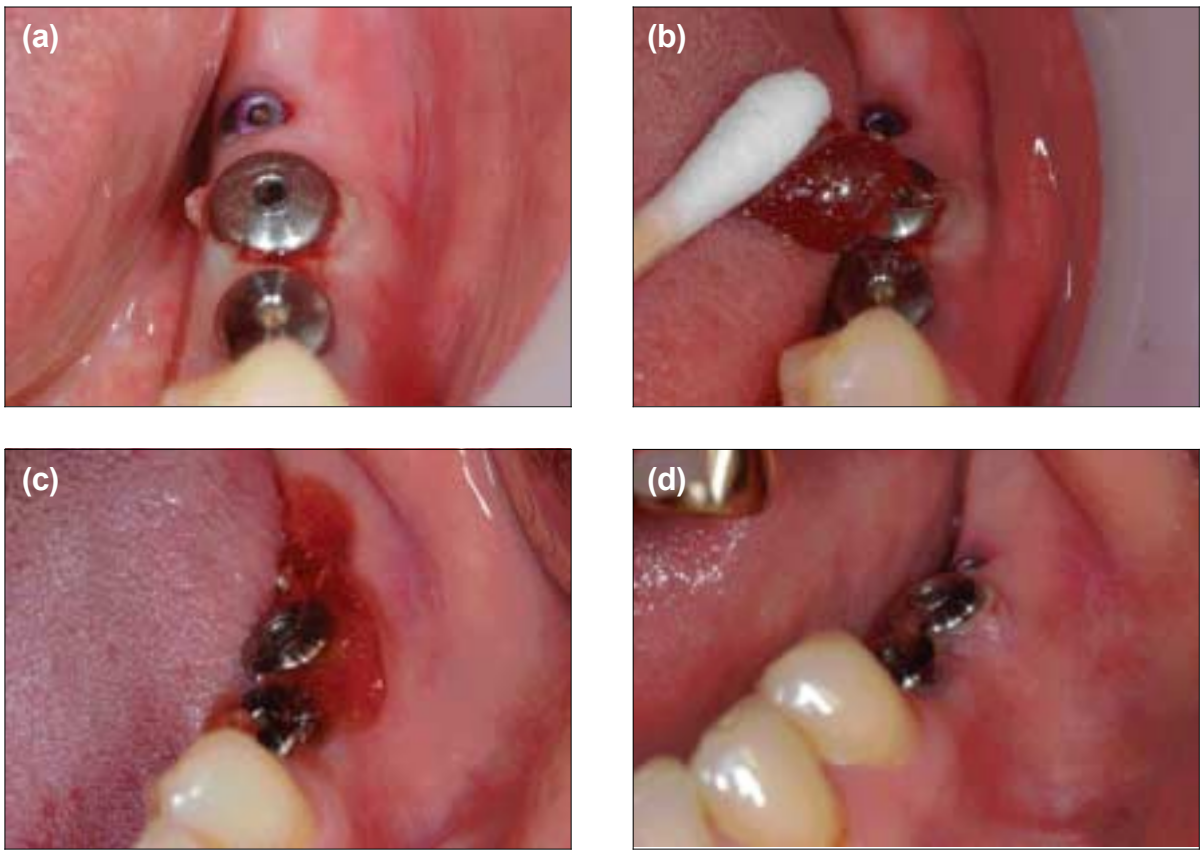


**Fig. 1.** These pictures show the process of recuperation after removing inflammation in implant operation. (a): Before applying gel, (b): Under applying gel, (c): Right after applying gel, (d): After 24hours.

Case 2: The NBF gingival gel was applied on a left buc- cal mucosa which had an erosion. After 24 hours the lesion subsided dramatically. Pain was also relieved.

Case 3: The NBF gingival gel was applied on a biopsy site of the right mandibular retromolar area. After 5days, the lesion was completely healed. Neither intraoral mouth rinse nor antibiotics were used. (Fig. 3)

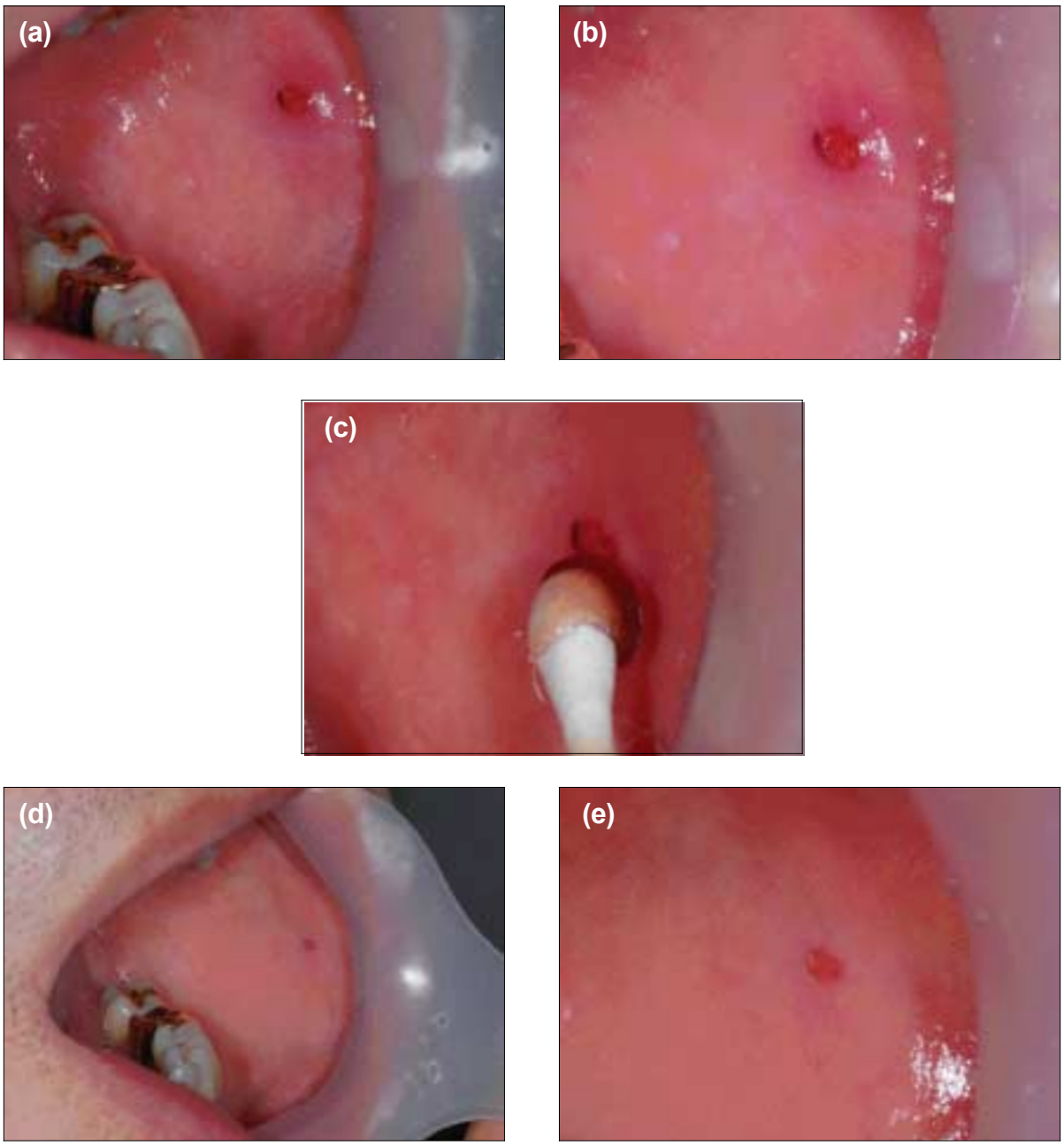


**Fig. 2.** These pictures show the process of recuperation from mucosa injury. (a, b): Before applying gel, (c): Under applying gel, (d): After 24hours, (e): Being magnified picture after 24hours.

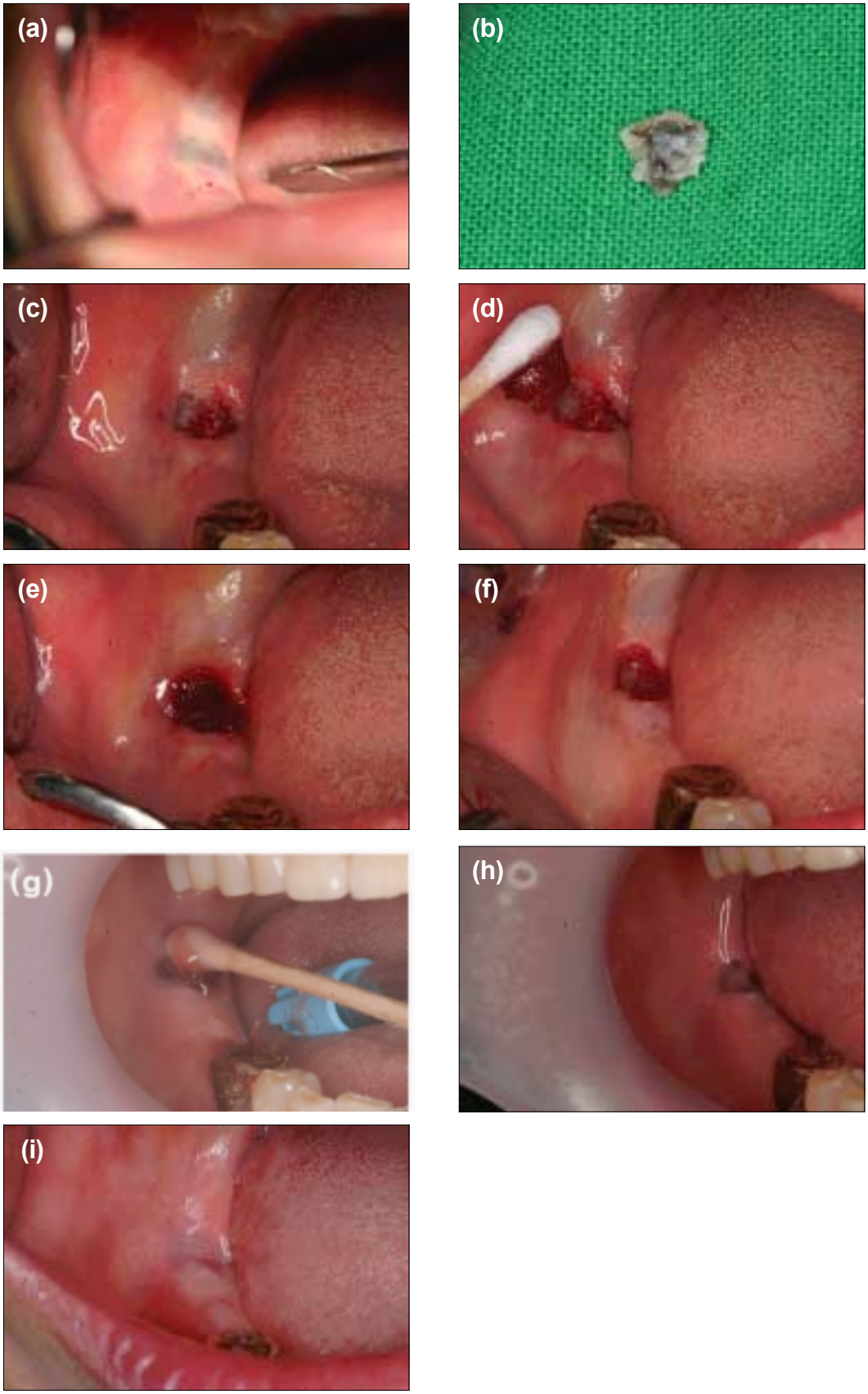


**Fig. 3.** These pictures show the process of recuperation after applying gel to wound removed soft tissue.
(a): Before removing soft tissue, (b): A soft tissue was removed by operation, (c): A wound of removing tissue, (d): The process of applying gel to wound, (e): After applying gel, (f): After 24hours, (g): The process of applying gel to wound again after 2days, (h): After 2days, (i): Perfectly recuperation after 5days.

Case 4: Erosion on the buccal mucosa of a woman in her 40s was rapidly healed 24 hours after applying NBF gingival gel.

Case 5: NBF gingival gel was applied after curettage of the gingival abscess. It also showed good healing after 24 hours.(Fig. 5)

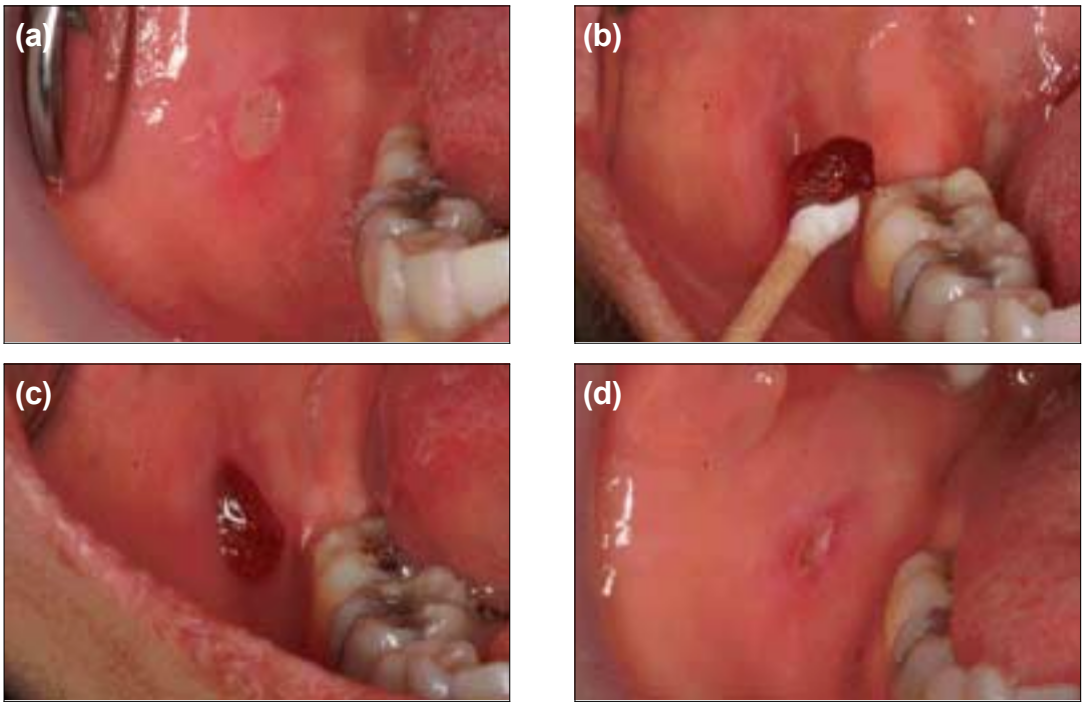


**Fig. 4.** These pictures show the process of applying gel to ulcer injury. (a): Before applying gel, (b): Under applying gel, (c): Right after applying gel, (d): After 24hours.

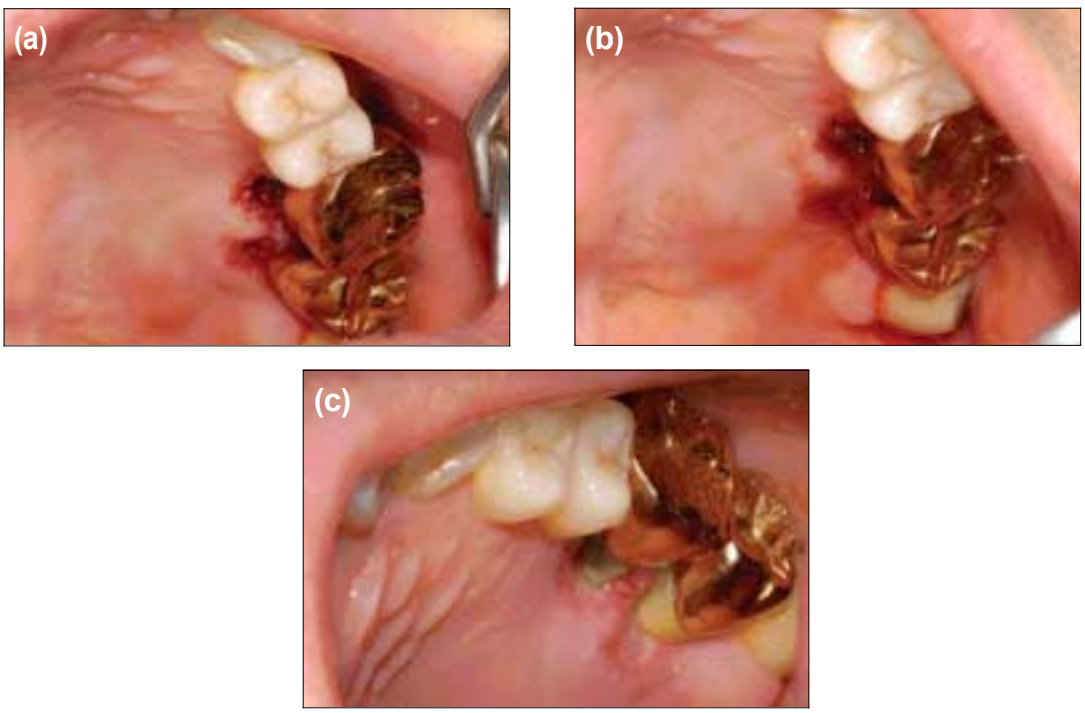


**Fig. 5.** These pictures show rapid healing after treatment of periodontal abscess. (a): Before applying gel, (b): Right after applying gel, (c): After 24hours.

## SUMMARY AND DISCUSSION

This study is a case report of a effectiveness of the NBF gingival gel on a gingival disease, erosion, and other oral lesions based on studies of nanoemulsion and its effects on prevention and treatment of gingival diseases. In Fig. 1, A flapless implant was placed on the right mandibular molar area. The patient showed gingival bleeding and redness which indicated actue inflammation. Under local anesthesia, curettage was done and NBF gingival gel was applied. After 24 hours, inflammatory signs including bleeding and redness were within normal range, and healing was accelerated. In Fig. 2, a 40-year-old patient showing an erosion on the left buccal mucosa was treated with NBF gingival gel which resulted in good healing after 24 hours. Fig. 3 shows a biopsy site of the right mandibular retromolar area. After 5days, the lesion was completely healed without the usage of neither antibi- otics nor oral gargling agents. Fig. 4 shows an erosion on the buccal mucosa of a woman in her 40s which was rapidly healed 24 hours after applying the NBF gingival gel. Fig. 5 shows rapid healing of the periodontal tissue after the periodontal abscess was treated. In all of the cases no other medicines were used in combination with the NBF gingival gel.

When treatment is done on intraoral lesions, due to decreased immunity and bleeding, infection and inflammation could arise and these could lead to serious condi- tions. Gingival swelling, redness and spontaneous bleed- ing are the common signs of gingival diseases. Also ero- sions are commonly seen in the mouth. Stomatitis which shows white plaques cause severe pain, burning sensa- tion, and bleeding. Lichen planus and aphthous ulcers are common and these are often caused by decreased immunity, malnutrition and infection.

In the treatment of gingival diseases antibiotics and NSAIDs are often used. Gingival pastes containing sodium chlorphyline, tetracycline, chlorolysozyme, tochoper- ol calcium and hyaluronic acid are often used, and these materials are shown effective. However side effects are still in research. These gingival medicaments are divided into p.o. medication and topical medication. P.o. medica- tion could lead to gastrointestinal discomfort, and the topical medications are hard to retain in mouth due to a highly humid intraoral environment. In todays society in which 30% of the people aged over 30 and 70% of people who are over 60 years old are suffering from periodontal disease, development of an effective medication for gingival diseases is very important.

## CONCLUSION

There is a limited medication for effective treatment of gingival diseases, post-implant inflammations, erosion, ulcers, dry mouth, gingivitis and redness due to decreased immunity. Also, there have been demands for appropriate materials that stay long in the moist oral environment. We have applyed the NBF gingival gel which is a highly functional paste made up of nanoemul- sion and observed its effects on gingival lesions and favorable results were observed without using antibi- otics or mouth rinses in addition to the gel.

Nanoemulsion containing antioxidants like vitamin C and vitamin E, and propolis which has antibacterial and antiinflammatory effects protects intraoral soft tissues and heals lesions rapidly which contributes to an augmentation of the quality of life. Favorable results of healing and protection were obtained which were reported in this study.

## REFERENCES


1. Suri SS, Fenniri H, Singh B: Nanotechnology-based drug delivery systems. J Occup Med Toxicol 2007 Dec 1;2(1):16.
2. Rajan P Kulkarni: Nano-Bio-Genesis: tracing the rise of nanotechnology and nanobiotechnology as‘big science.J Biomed Discov Collab 2007;2.
3. OV Salata: Applications of nanoparticles in biology and medicine. J Nanobiotechnology 2004;2:3.
4. Amit K. Gupta, Pradeep R. Nair, Demir Akin, Michael R. Ladisch, Steve Broyles, Muhammad A. Alam, and Rashid Bashir; Anomalous resonance in a nanomechanical biosensor. Proc Natl Acad Sci USA. 2006 September 5;103(36):13362-13367.
5. Ernie Hood: Nanotechnology: Looking As We Leap. Environ Health Perspect. 2004 September; 112(13).
6. Anandan V, Rao YL, Zhang G: Nanopillar array structures for enhancing biosensing performance. Int J Nanomedicine 2006;1(1):73-9.
7. JØrnung J, Fardal O: Perceptions of patients’smiles: a comparison of patients’and dentists’opinions. J Am Dent Assoc 2007 Dec; 138(12):1544-53.
8. Rosa DS, Aranha AC, Eduardo Cde P, Aoki A: Esthetic treatment of gingival melanin hyperpigmentation with Er:YAG laser: short-term clinical observations and patient follow-up. J Periodontol 2007 Oct;78(10):2018-25.
9. Pradeep AR, Kumar MS, Ramachandraprasad MV, Shikha C: Gingival crevicular fluid levels of neopterin in healthy subjects and in patients with different periodontal diseases. J Periodontol 2007 Oct;78(10):1962-7.
10. Villa AA: Clinical, biochemical and histopatological correlacio ´ n in diabetic patiens with periodontal disease. Rev Fac Cien Med Univ Nac Cordoba 2006;63(2 Suppl):50-5.
11. Changh-Hoon Chae, Jun-Woo Park: The study on the effect

of nanoemulsion of gingival inflammation. J Kor Oral Maxillofac Surg 2007;33:419-425.
12. Studen-Pavlovich D, Ranalli DN: Periodontal and soft tissue prevention strategies for the adolescent dental patient. Dent Clin North Am 2006 Jan;50(1):51-67.
13. Ali AA, Suresh CS: Oral lichen planus in relation to transaminase levels and hepatitis C virus. J Oral Pathol Med 2007 Nov;36(10):604.
14. Pistorius A, Martin M, Willershausen B, Rockmann P: The clinical application of hyaluronic acid in gingivitis therapy. Quintessence Int 2005 Jul-Aug;36(7-8):531-8.